

## CASE REPORT

# Correct diagnosis and successful treatment for pericardial effusion due to toothpick injury: A case report and literature review

Yu-Yin Liu, Jeng-Hwei Tseng, Chun-Nan Yeh, Ji-Tseng Fang, Hsiang-Lin Lee, Yi-Yin Jan

Yu-Yin Liu, Chun-Nan Yeh, Hsiang-Lin Lee, Yi-Yin Jan, Department of Surgery, Chang Gung Memorial Hospital, Chang Gung University, Taiwan, China  
Jeng-Hwei Tseng, Department of Radiology, Chang Gung Memorial Hospital, Chang Gung University, Taiwan, China  
Ji-Tseng Fang, Department of Internal Medicine, Chang Gung Memorial Hospital, Chang Gung University, Taiwan, China  
Correspondence to: Chun-Nan Yeh, MD, Department of Surgery, Chang Gung Memorial Hospital, Chang Gung University, 5, Fu-Hsing Street, Kwei-Shan, Taoyuan, Taiwan, China. ycn@adm.cgmh.org.tw  
Telephone: +886-3-3281200 Fax: +886-3-3285818  
Received: 2007-04-11 Accepted: 2007-05-12

## Abstract

We reported a 55-year-old man who suffered from chest pain and dyspnea on exertion for two weeks associated with night sweating, general malaise, poor appetite, and body weight loss. Physical examination revealed friction rub with distant heart sound, bilateral clear breathing sound, no abdomen tenderness, and normal bowel sound. Subsequent chest X-ray revealed cardiomegaly and cardiac echo showed massive pericardial and pleural effusion with normal left ventricular function. Constrictive pericarditis was diagnosed based on clinical information. Tuberculosis (TB), malignancy, autoimmune disease, infection, hypothyroidism, and idiopathic could be the causes but excluded by further study. High-resolution lung CT scan after reconstruction revealed a moderate amount pericardial effusion with possible superimposed infection. Thickness of pericardium and left lobe liver abscess were found. A straight tubular structure about 6 cm in length transverses the lateral segment of liver to pericardial space and unknown foreign body was suspected. Laparotomy was performed, 6.5 cm toothpick was found through the liver into pericardium. Post-operative course was uneventful and he discharged one week later. The patient could not remember swallowing the toothpick before. He had no chest pain and dyspnea on exertion during a 6-mo follow-up period.

© 2007 WJG. All rights reserved.

**Key words:** Toothpick injury; Pericardial effusion; Laparotomy

Liu YY, Tseng JH, Yeh CN, Fang JT, Lee HL, Jan YY. Correct

diagnosis and successful treatment for pericardial effusion due to toothpick injury: A case report and literature review. *World J Gastroenterol* 2007; 13(31): 4278-4281

<http://www.wjgnet.com/1007-9327/13/4278.asp>

## INTRODUCTION

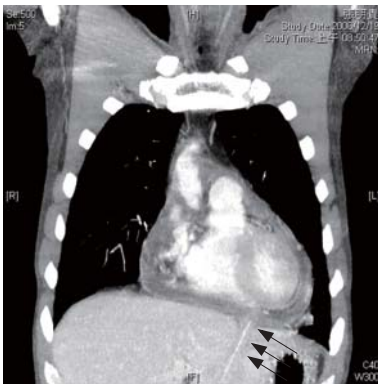
Toothpick is a common cause of foreign body ingestion. It usually resulted in perforation of gastrointestinal tract with life-threatening peritonitis. In some conditions, it may cause inflammatory mass formation while penetrating into solid organs such as liver<sup>[1-10]</sup> or pancreas<sup>[11]</sup> instead of hollow organ. Mis-swallowing of toothpick is always hard to be diagnosed and the definite diagnosis is usually made during surgery because toothpick could be demonstrated on image study in only 14% cases and the patient always did not remember this event<sup>[12]</sup>.

Pericardial injury by toothpick is very rare and totally two cases have been reported in the literature<sup>[13,14]</sup>. We conducted a systemic review of the literature of injury from ingested toothpick with migration into liver and heart. To our knowledge, we reported the first case of pericardial effusion due to toothpick injury correctly diagnosed preoperatively and receiving successful treatment with uneventful postoperative course.

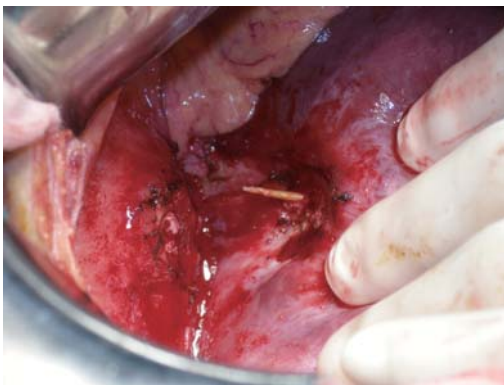
## CASE REPORT

The 55-year-old man was quite well but suffered from chest pain and dyspnea on exertion until two weeks ago before admission in December 2006. The pain was vague and compressive, especially at the right chest, and aggravated by exercise and when the patient was lying at right decubitus position. In addition, the patient complained of night sweating, general malaise, poor appetite, and body weight loss. He had hypertension and took anti-hypertensive drug regularly, and no history of other diseases.

On admission, his blood pressure was 150/70 mmHg, heart rate 89 beats/min, respiratory rate 20 breaths/min, and temperature 36.8°C. There was no vomiting, jaundice, dysuria, chills, or abdominal distention. Physical examination revealed friction rub with distant heart sound, bilateral clear breathing sound, no abdomen tenderness,



**Figure 1** High resolution chest computed tomography (CT) revealed a moderate amount of pericardial effusion with possible superimposed infection. Thickness of pericardium and left lobe liver abscess were found. A straight tubular structure about 6 cm in length transverse the lateral segment of liver to pericardial space and unknown foreign body was suspected.



**Figure 2** Operative findings revealed severe adhesion between liver and diaphragm. After the space was divided between the liver and diaphragm, a toothpick was found through the liver into pericardium.

and normal bowel sound. The following laboratory data were recorded: white blood count 9900 cell/ $\mu$ L (5000-10000 cell/ $\mu$ L), hemoglobin 12.1 (14-17) g/dL, total bilirubin 0.7 (0.0-1.3) mg/dL, BUN 21 (6-21) mg/dL, creatinine 1.2 (0.4-1.4) mg/dL, albumin 3.9 (3.5-5.5) g/dL, negative hepatitis B surface antigen and hepatitis C antibody, negative urine analysis. Subsequent chest X-ray revealed cardiomegaly and cardiac echo showed massive pericardial effusion and pleural effusion with normal left ventricular function.

Constrictive pericarditis was diagnosed based on clinical information. Tuberculosis (TB), malignancy, autoimmune disease, infection, hypothyroidism, and idiopathic could be the causes. Subsequent sputum TB smear showed negative acid-fast stain. Analysis of pleural effusion was recorded as follows: LDH 70 U/L, glucose 111 mg/dL, and WBC 1765 cell/ $\mu$ L ( $< 100$  cell/ $\mu$ L). Cytology of pleural effusion revealed no malignant cell. Pleural effusion smear was negative for bacteria or acid-fast stain. Autoimmune antibody study showed C3: 188 (90-180) mg/dL, C4 60.5: (10-40) mg/dL, and negative antinuclear antibody (ANA) ( $< 1:80$ ). Tumor marker revealed CEA 1.33 ( $< 5$ ) ng/mL and AFP 3.5 ( $< 15$ ) ng/mL. Thyroid function



**Figure 3** Gross findings of a toothpick measuring 6.5 cm in length.

**Table 1** Summary of mis-swallowing of toothpick migrating into other organs from gastrointestinal tract in the literature

Migration organs	Origin	<i>n</i>
Heart <sup>[13,14]</sup>	Unknown	2
Liver <sup>[1-10]</sup>	Stomach	5
	Duodenum	3
	Unknown	2
Vessel <sup>[15-20]</sup>	Duodenum	4
	Small bowel	1
	Unknown	1
Pancreas <sup>[12]</sup>	Duodenum	1
Ureter <sup>[21]</sup>	Cecum	1
Bladder <sup>[22]</sup>	unknown	1

test showed TSH: 0.715 (0.35-5.5)  $\mu$ IU/mL and free-T4: 1.22 (0.89-1.76) ng/dL. Common causes of constrictive pericarditis were all excluded.

Because of his unusual presentation, we arranged the high-resolution lung CT scan. CT scan after reconstruction revealed a moderate amount of pericardial effusion with possible superimposed infection. Thickness of pericardium and left lobe liver abscess were found. A straight tubular structure about 6 cm in length transversed the lateral segment of liver to pericardial space and unknown foreign body was suspected (Figure 1).

Because of progression of symptom and sign, laparotomy was performed and severe adhesion was found between the liver and diaphragm and the other adhesion was localized between lesser curvature of the stomach and lateral segment of the liver. After dividing the space between the liver and diaphragm, we found a 6.5-cm toothpick through the liver into pericardium (Figures 2 and 3). The toothpick was removed and pericardium was open for drainage of pericardial effusion. Fibrin-coating material was found in pericardial space. Post-operative course was uneventful and he discharged one week later. The patient could not remember swallowing the toothpick before. He had no chest pain and dyspnea on exertion during a 6-mo follow-up period.

## DISCUSSION

Toothpick is a common cause of foreign body ingestion, however, 80%-90% of ingested toothpick pass through

Table 2 Summary of toothpick migrating into liver

Case No.	Age/Sex	S/S	Pre-op diagnosis of FB	Perforation or peritonitis	Treatment	Primary site of toothpick	Mortality
1 <sup>[1]</sup>	59/M	RUQ pain	Yes	-	Antibiotics	Duodenum	Nil
2 <sup>[2]</sup>	63/M	RUQ pain cholangitis	Negative (liver pseudotumor)	-	Lapa	Stomach	Nil
3 <sup>[3]</sup>	48/F	RUQ pain	Negative (Liver abscess)	-	Lapa	Stomach	Nil
4 <sup>[4]</sup>	59/M	RUQ pain fever	Yes	-	Lapa	Stomach	Nil
5 <sup>[5]</sup>	NA	NA	Endoscope dx	-	Endo	Stomach	Nil
6 <sup>[6]</sup>	48/M	RUQ pain	Negative (Liver abscess)	-	Lapa	Duodenum	Nil
7 <sup>[7]</sup>	52/M	BW loss	Yes	-	Lapa	Duodenum	Nil
8 <sup>[8]</sup>	NA	NA	Negative (Liver abscess)	Unknown	Unknown	Unknown	NA
9 <sup>[9]</sup>	NA	NA	Negative (Liver abscess)	Unknown	Unknown	Stomach	NA
10 <sup>[10]</sup>	NA	NA	Negative (Liver abscess)	NA	NA	NA	NA

M: male; F: female; S/S: symptom/sign; Pre-op: preoperative; FB: foreign body; RUQ: right upper quadrant; BW: body weight; NA: not available; Lapa: laparotomy; Endo: endoscopy.

Table 3 Summary of toothpick migrating into heart

Case No.	Age/Sex	S/S	Pre-op diagnosis of FB	Perforation or peritonitis	Treatment	Primary site	Post-op diagnosis	Mortality
Case 1 <sup>[13]</sup>	67/F	Chest pain Tamponade	Negative	Negative	Sternotomy	NA	Toothpick migrating to pericardium and right coronary artery laceration	Nil
Case 2 <sup>[14]</sup>	53/M	Dyspnea Chest pain Fever	Negative	Negative	Sternotomy	Diaphragm site of heart	Toothpick migrating to pericardium	Nil
Our case	55/M	Dyspnea Chest pain	Positive	Negative	Laparotomy	Stomach	Toothpick migrating to pericardium through liver	Nil

M: male; F: female; S/S: symptom/sign; Pre-op: preoperative; FB: foreign body; NA: not available.

the gastrointestinal tract without any complication<sup>[15]</sup>. It may sometimes result in the perforation of gastrointestinal tract with life-threatening peritonitis. It rarely causes inflammatory mass formation while penetrating into solid organs such as liver or pancreas. Similar to this case, few patients (12%) remember swallowing a toothpick. The onset of symptoms ranged in a wide variation from less than one day to 15 years. As demonstrated in this case, toothpicks could be identified by imaging studies, but only seen in 14% of the cases. The definitive diagnosis was most commonly made at laparotomy (53%) and followed by endoscopy (19%), with an overall mortality rate of 18%<sup>[12]</sup>.

Totally, 170 articles have been identified and the origin site of toothpick can be identified in 62 cases in the literature (Table 1). Among them, 21 patients had different complications due to migration of toothpicks to a solid organ or vessels<sup>[11,13-22]</sup>. Migration from gastrointestinal tract comprised 30% cases and 38.5% of those are from duodenum. If cases presenting with liver abscess or pseudotumor, gastrointestinal bleeding, sepsis, hematuria instead of the symptom of hollow organ perforation increased the difficulty of pre-operative diagnosis.

Migration of a toothpick to the liver was reported in 10 cases (Table 2) and usually occurred in old male patients with right upper quadrant pain and cholangitis<sup>[1-10]</sup>. An inflammatory mass mimicking liver abscess and pseudotumor with the picture of hepatocellular carcinoma or cholangiocarcinoma could be demonstrated in the image study. Among them, four cases had a definite diagnosis

before operation with advanced image study. The origin of migration to the liver is duodenum or stomach.

Acute pericarditis is a clinical syndrome with many possible causes, including idiopathic, viral, neoplastic disease, heart surgery, myocardial infarction, autoimmune disease, infection, and foreign body. More than 90% cases resulted from idiopathic or viral cause<sup>[23]</sup>. Presentation of constrictive pericarditis due to complication of ingested toothpick is sporadically reported<sup>[13,14]</sup>. Different from the previous two reported cases, we had a definitive and correct pre-operative diagnosis (Table 3). We also clearly revealed a straight tubular structure transversing the lateral segment of the liver to pericardial space caused by an unknown foreign body with reconstructive chest computed tomography.

In conclusion, we clearly demonstrated and successfully diagnosed and treated a case with migration of toothpick form stomach through liver into pericardium.

## REFERENCES

- Chiang TH, Liu KL, Lee YC, Chiu HM, Lin JT, Wang HP. Sonographic diagnosis of a toothpick traversing the duodenum and penetrating into the liver. *J Clin Ultrasound* 2006; **34**: 237-240
- Del Fabbro D, Torzilli G, Gambetti A, Leoni P, Gendarini A, Olivari N. Liver inflammatory pseudotumor due to an intrahepatic wooden toothpick. *J Hepatol* 2004; **41**: 498
- Kanazawa S, Ishigaki K, Miyake T, Ishida A, Tabuchi A, Tanemoto K, Tsunoda T. A granulomatous liver abscess which developed after a toothpick penetrated the gastrointestinal tract: report of a case. *Surg Today* 2003; **33**: 312-314

- 4 **Cheung YC**, Ng SH, Tan CF, Ng KK, Wan YL. Hepatic inflammatory mass secondary to toothpick perforation of the stomach: triphasic CT appearances. *Clin Imaging* 2000; **24**: 93-95
- 5 **Guglielminetti D**, Poddie DB. Liver abscess secondary to ingestion of foreign body. A case report. *G Chir* 1999; **20**: 453-455
- 6 **Drnovsek V**, Fontanez-Garcia D, Wakabayashi MN, Plavsic BM. Gastrointestinal case of the day. Pyogenic liver abscess caused by perforation by a swallowed wooden toothpick. *Radiographics* 1999; **19**: 820-822
- 7 **Zambrana JL**, Garcia-Gutierrez JA, Diez F. Subphrenic abscess related to the ingestion of a toothpick. *N Engl J Med* 1998; **338**: 133-134
- 8 **Tsui BC**, Mossey J. Occult liver abscess following clinically unsuspected ingestion of foreign bodies. *Can J Gastroenterol* 1997; **11**: 445-448
- 9 **Allimant P**, Rosburger C, Zeyer B, Frey G, Morel E, Bietiger M, Dalcher G. An unusual cause of hepatic abscess. *Ann Gastroenterol Hepatol (Paris)* 1990; **26**: 5-6
- 10 **Rafizadeh F**, Silver H, Fieber S. Pyogenic liver abscess secondary to a toothpick penetrating the gastrointestinal tract. *J Med Soc N J* 1981; **78**: 377-378
- 11 Kim KH, Woo EY, Rosato EF, Kochman ML. Pancreatic foreign body: Ingested toothpick as a cause of pancreatitis and hemorrhage. *Gastrointest Endosc* 2004; **59**: 147-150
- 12 **Li SF**, Ender K. Toothpick injury mimicking renal colic: case report and systematic review. *J Emerg Med* 2002; **23**: 35-38
- 13 **Braconi L**, Pretelli P, Calamai G, Montesi G, Romagnoli S, Gelsomino S, Bevilacqua S, Stefano P, Gensini GF. An unusual case of cardiac tamponade. *J Cardiovasc Med (Hagerstown)* 2006; **7**: 219-221
- 14 **Meyns BP**, Faveere BC, Van de Werf FJ, Dotremont G, Daenen WJ. Constrictive pericarditis due to ingestion of a toothpick. *Ann Thorac Surg* 1994; **57**: 489-490
- 15 **Schwartz JT**, Graham DY. Toothpick perforation of the intestines. *Ann Surg* 1977; **185**: 64-66
- 16 **Rioux M**, Lacourciere L, Langis P, Rouleau M. Sonographic detection of ingested foreign bodies in the inferior vena cava. *Abdom Imaging* 1997; **22**: 108-110
- 17 **Dicicco BS**, Heit HA, Peterson JE, Harshaw WG, Cooper JN. Massive bleeding due to arterial-enteric fistula from an ingested toothpick. *J Clin Gastroenterol* 1985; **7**: 292-295
- 18 **Allen B**, Krupski WC, Wylie EJ. Toothpick perforation of the inferior vena cava. *West J Med* 1983; **138**: 727-730
- 19 **Fry D**, Flint LM, Richardson JD. Aorticoduodenal fistula secondary to a toothpick. *J Ky Med Assoc* 1978; **76**: 441
- 20 **Justiniani FR**, Wigoda L, Ortega RS. Duodenocaval fistula due to toothpick perforation. *JAMA* 1974; **227**: 788-789
- 21 **Plavcan WG**, McWilliams WA. Toothpick obstruction of the ureter. *J Urol* 1988; **139**: 114-115
- 22 **Alagiri M**, Rabinovitch HH. Toothpick migration into bladder presents as abdominal pain and hematuria. *Urology* 1998; **52**: 1130-1131
- 23 **Sagrista Sauleda J**, Permanyer Miralda G, Soler Soler J. Diagnosis and management of acute pericardial syndromes. *Rev Esp Cardiol* 2005; **58**: 830-841

S- Editor Zhu LH L- Editor Ma JY E- Editor Liu Y